Journal of Plastic, Reconstructive & Aesthetic Surgery (2017) 70, 1001—1008

Innervated dorsoradial perforator free flap: A reliable supermicrosurgery fingertip reconstruction technique

Dajiang Song [a,g], Georgios Pafitanis [b,g], Peng Yang [c], Mitsunaga Narushima [d], Zan Li [a], Linfeng Liu [e,*], Zengtao Wang [f]

[a] *Department of Oncology Plastic Surgery, Hunan Province Cancer Hospital and The Affiliated Cancer Hospital of Xiangya School of Medicine, Central South University, Changsha, Hunan 410000, China*
[b] *The Royal London Hospital, Barts Health NHS Trust, Queen Mary University of London, London, UK*
[c] *Department of Orthopedics Trauma Surgery, Changzheng Hospital, The Second Military Medical University, Shanghai 200000, China*
[d] *Department of Plastic and Reconstructive Surgery, University of Tokyo, 7-3-1 Hongo, Bunkyo-ku, Tokyo 1138655, Japan*
[e] *Department of Hand and Foot Surgery, Jinan Municipal Hospital of Traditional Chinese Medicine, Jinan, Shandong 250000, China*
[f] *Hand and Foot Surgical Center, Shandong Provincial Hospital Affiliated to Shandong University, Jinan, Shandong 250000, China*

Received 21 November 2016; accepted 17 May 2017

KEYWORDS
Fingertip reconstruction;
Dorsoradial flap;
Innervation;
Supermicrosurgery

Summary *Introduction:* This study demonstrates the use of a modified free innervated DRAP flap utilizing the supermicrosurgery technique for fingertip reconstruction.
Materials and methods: From January 2010 to February 2014, 20 cases of fingertip reconstruction were performed using a short pedicle mini innervated transverse DRAP flap. The patients demographics, the mechanism of injury, the defect size and anatomical location, the source of pedicle vessels, the recipient vessels, the nerve branch used for innervation, the follow-up and sensation outcomes are reported. Three cases are presented demonstrating different anatomical fingertip injury reconstructions.
Results: 20 consecutive traumatic fingertip injuries (M:F-14:6) were reconstructed with a free DRAP flap from the same hand. 6 index, 6 middle, 5 ring and 3 little finger defects were included in this study. All procedures were performed under regional anaesthesia and sedation. There were no intra- or post-operative complications. The average operative time was 105 (85—120) minutes. Each flap size was matching the size of the defects. All donor sites

* Corresponding author.
E-mail addresses: johnsondan@163.com (D. Song), g.pafitanis@qmul.ac.uk (G. Pafitanis), paytonyang@outlook.com (P. Yang), sancho-ps@umin.ac.jp (M. Narushima), zzanli@163.com (Z. Li), wuzedongpro@163.com (L. Liu), submit_pro@163.com (Z. Wang).
[g] The first and second authors contributed equally for this manuscript.

http://dx.doi.org/10.1016/j.bjps.2017.05.038
1748-6815/© 2017 British Association of Plastic, Reconstructive and Aesthetic Surgeons. Published by Elsevier Ltd. All rights reserved.

achieved primary closure and good cosmesis. The average follow-up was 12.8 (6—28) months. Follow-up demonstrated a static two-point discrimination of the flaps with an average distance of 5.5 (4—7) mm.
Conclusion: The innervated DRAP flap has proven to be an easy, reliable and effective sensate fingertip reconstruction option, utilizing the supermicrosurgery technique.
Level of Evidence: Level IV, retrospective series.
© 2017 British Association of Plastic, Reconstructive and Aesthetic Surgeons. Published by Elsevier Ltd. All rights reserved.

Introduction

Fingertip defects reconstruction is challenging.[1] Cosmesis and sensitivity are essential for good reconstructive outcomes. Traditional methods include cross-finger flap[2] and digital artery perforator flap.[3] Current literature reports various free flap options such as toe flap,[4] thenar flap,[5] lateral arm flap,[6] posterior inter-osseous flap[7] venous flap,[8] dorsoulnar perforator flap[9] and medial plantar perforator flaps.[10] Several reconstructive challenges concerning the scar size, flap bulkiness, sensitivity, donor site morbidity and technical challenges due to the small caliber of the recipient vessels are limiting the use of free flaps in this reconstructive modality.

The dorsoradial artery perforator (DRAP) flap has been previously described as a local perforator based option for small to moderate size defects in the forearm, hand, and proximal finger regions.[11] This flap has also demonstrated its effectiveness in large finger proximal defects. However, it is technically challenging and unable to be used for distal fingertip reconstruction.[11] The use of a free DRAP flap for fingertip reconstruction has been limited. This study demonstrates the use of modified innervated free DRAP flap utilizing the supermicrosurgery technique for fingertip reconstruction.

Materials and methods

Anatomy

The radial artery at the level of the dorsal aspects of the radial metaphysis, gives the dorsal carpal arterial arch passing deeper to the extensor pollicis brevis, extensor carpi radialis longus and extensor carpi radialis brevis tendons. As it descends, it crosses the superficial branch of radial nerve and gives the dorsal intermetacarpal arteries before it merges with the ulnar dorsal arch. The dorsoradial skin is supplied by a small cutaneous constant perforator vessel, originating from the dorsal arterial network, formed by the dorsal radial arch which connects to the dorsal ulnar artery[12,13] (Figure 1A).

Patients and methods

From January 2010 to February 2014, 20 consecutive patients (M:F-14:6) with an average age of 26.5 (17—35) who presented with soft tissue fingertip defects, underwent reconstruction with a DRAP free flap. For all cases, demographics, mechanism of injury, site and size of defect, source of pedicle vessels, recipient vessels, nerve branch used for innervation, follow-up and sensation outcomes are reported. All cases suffered traumatic injuries with 13 cases presenting with crushing injury and 7 cases with avulsion injury. There were 12 right and 8 left hands, with the location of the skin defect on 6 index, 6 middle, 5 ring and 3 little fingertips. The size of fingertip skin defects ranged from 1.5 × 1.6 cm to 2.5 × 3 cm with surface area of 3.8 (2.3—6) cm^2. In all cases, the underlying bone and tendons were exposed (Table 1).

All cases had a pre-operative hand-held Doppler investigation to identify the location of the dorsal radial cutaneous artery on the same site of the injured hand. The free flap skin island was designed along the Langer lines in a fusiform fashion, over the dorsoradial aspect of the wrist to make the size of each designed flap match the size of the fingertip defects. Three cases are presented demonstrating different anatomical fingertip injury reconstructions.

The surgical technique

The operation is performed under regional anaesthesia combined with intravenous sedation, from a senior microsurgeon with experience in supermicrosurgery and small caliber vessels free tissue transfer. A pneumatic tourniquet is required to achieve bloodless technique. Wound debridement and evaluation of the associate underlying structures injuries was performed.

The flap can be designed transversely or longitudinally (Figures 1A and B). Elevation starts from proximal to distal with the aid of loops magnification. One or two subcutaneous veins normally present in the radial borders are dissected and preserved for venous drainage. A radial incision is extended to assist the identification of a medial branch of the superficial branch of radial nerve, which is also dissected and preserved to offer innervation to the flap (Figure 1B). The abductor pollicis longus and extensors pollicis longus and brevis tendons are used as anatomical landmarks to identify the dorsal cutaneous radial artery and two venous comitantes (Figure 1C). A single distal stay suture retracting the elevated flap, is used to offer an extended operating field to perform deep micro-dissection, to obtain a pedicle length up to 2.5 cm.

The mini flap with the short DRA pedicle, along with the preserved cutaneous vein(s) and the small branch of the superficial branch of the radial nerve along with a thin layer

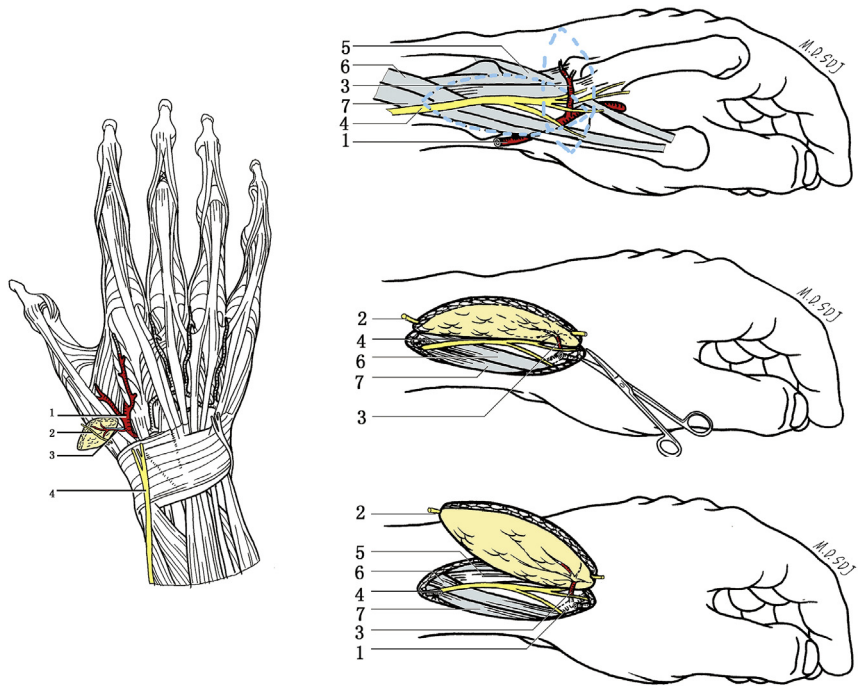

Figure 1 Schematic representation of DRAP flap design and elevation. 1: Radial artery; 2: Medial branch of the superficial branch of radial nerve; 3: Dorsal cutaneous radial artery; 4: Superficial branch of radial nerve; 5: Extensor pollicis longus tendon; 6: Extensor pollicis brevis tendon; 7: Abductor pollicis longus tendon.

of subcutaneous fat is designed and taken in the exact same size as the fingertip defect (Figure 1D). After flap elevation is completed, the tourniquet is released, to allow blood inflow from the DRA pedicle and blood outflow from the cutaneous veins to confirm flap status before transferring it to the fingertip defect. The DRA pedicle is then ligated and the free flap is transferred to the fingertip defect for the microvascular anastomosis and re-innervation. The donor site is primarily closed.

Under microscopic magnification (×12), the digital artery, distal from the distal inter-phalangeal joint crease, is used as a recipient vessel. After micro-dissection the arterial "squirt" test can confirm the blood inflow prior to arterial anastomosis. The dorsal cutaneous and volar subcutaneous veins are in close approximation to the arterial anastomosis and should be anastomosed to achieve adequate flap outflow. A 12-0 Nylon suture material with 80 μm needle was used in all anastomoses (Crownjun Kono Co., Tokyo, Japan).

Results

The free DRAP flaps from the same hands were performed to reconstruct all 20 consecutive traumatic fingertip injuries (M:F-14:6). 6 index, 6 middle, 5 ring and 3 little finger defects were included in this study. All procedures were performed under regional anaesthesia and sedation. The average operative time was 105 (85—120) minutes. The flap size ranged from 1.5 × 2.0 cm^2 to 2.0 × 3.0 cm^2. Each flap size was matched the size of the defect. All donor sites achieved primary closure and good cosmesis.

The DRAP flaps had double arterial pedicle in 12 cases and single arterial pedicle in 8 cases. The terminal branch of digital artery (DA) was used as recipient in 5 cases and the dorsal arterial branch in 7 cases, using the end-to-end anastomoses technique. A sensory branch from the medial branch of the radial nerve was always identified to ensure the innervated flap elevation. The branch of the superficial branch of radial nerve was coaptated with a terminal branch of the digital nerve in 11 cases, and the dorsal branch of the digital nerve in 9 cases. Subcutaneous veins were used for venous anastomoses in 18 cases, and volar venous branches were used in 2 cases. Double venous drainage was utilized in 14 cases.

There were no intra- or post-operative complications. All flaps survived and provided coverage of the defects. There was minimal donor site morbidity and primary closure was achieved in all cases with good cosmesis. There were no signs of any immediate complications of arterial insufficiency or venous congestion. Two cases presented with transient numbness at the donor site, but it recovered a few weeks after surgery. All patients followed the same physiotherapy protocol and started mobilizing from the second post-operative week. The average follow-up was 12.8 (6—28) months. Follow-up demonstrated a static two-point discrimination of the flaps with an average distance of 5.5 (4—7) mm.

Case reports

Case 1

A 35-year-old male sustained a crush injury of his right little finger, with soft tissue loss of the volar aspect of the distal phalanx (Figure 2A). A free DRAP flap 2.0 × 3.0 cm^2 was harvested from the same hand (Figure 2B). The colour and

Table 1 Clinical data from the 20 patients who underwent fingertip reconstruction with the innervated DRAP free flap.

No	Age	Gender	Mechanism of injury	Finger	Size of defects (cm^2)	Size of flaps (cm^2)	Pedicle length (cm)	Pedicle Caliber (mm)	Operative time (min)	Recipient artery	Recipient vein	Recipient nerve	P-D TEST (mm)	Follow-up (months)	Complication
1	28	M	Crush	LRF	1.5 × 2.5	2.0 × 3.0	1.7	0.9	100	RDA	2 DCV	TBRDN	6.0	16	No
2	21	F	Crush	LMF	2.0 × 2.5	2.5 × 2.5	1.3	0.9	110	RDA	1 VSV	DDN	4.5	24	No
3	35	M	Crush	RLF	1.5 × 2.0	2.0 × 3.0	2.1	0.8	95	UDA	2 VSV	TBRDN	4.0	28	No
4	31	M	Crush	RMF	1.5 × 1.5	1.5 × 1.6	0.9	0.7	120	RDA	1 VSV	TBRDN	5.5	9	No
5	32	M	Crush	RRF	2.0 × 2.5	2.5 × 3.0	1.9	1.0	85	UDA	1 VSV	TBRDN	7.0	12	No
6	32	M	Crush	LRF	1.5 × 2.0	2.0 × 2.5	1.5	0.8	90	UDA	1 DCV	TBRDN	5.0	10	No
7	20	M	Crush	LRF	1.5 × 2.0	2.0 × 2.5	2.3	1.0	120	UDA	2 DCV	DDN	4.0	28	No
							1.7	0.7		RDA					
8	30	M	Crush	LRF	1.5 × 1.5	1.5 × 2.0	2.0	0.8	110	RDA	1 DCV, 1 VSV	DDN	4.5	12	No
							1.6	0.7		UDA					
9	24	F	Crush	LIF	1.5 × 2.0	1.5 × 2.5	1.0	0.7	100	RDA	1 DCV	DDN	5.0	10	No
10	22	F	Crush	LMF	2.0 × 2.5	2.0 × 3.0	2.0	1.0	120	RDA	2 DCV	TBRDN	5.5	10	No
							1.7	0.8		UDA					
11	19	M	Crush	RIF	1.5 × 2.0	1.5 × 2.5	1.8	0.8	105	RDA	2 DCV	DDN	6.0	9	No
12	31	F	Crush	RIF	2.0 × 3.0	2.0 × 3.5	1.6	1.0	95	RDA	2 DCV	DDN	5.5	10	No
13	17	M	Crush	LLF	1.5 × 2.5	2.0 × 3.0	1.0	0.7	100	UDA	2 DCV	DDN	5.5	8	No
14	30	F	Crush	RMF	1.5 × 2.5	1.5 × 3.0	1.0	0.7	105	UDA	1 DCV, 1 VSV	TBRDN	5.0	12	No
15	27	M	Crush	RIF	2.0 × 2.5	2.0 × 3.0	2.0	1.0	120	RDA	1 DCV, 1 VSV	TBRDN	6.0	10	No
							1.8	0.7		UDA					
16	25	M	Crush	RMF	2.0 × 3.0	2.0 × 3.5	1.9	0.8	120	UDA	2 DCV	DDN	5.5	14	No
17	26	F	Crush	LLF	1.5 × 1.6	1.5 × 2.0	2.0	1.0	120	RDA	1 DCV, 1 VSV	TBRDN	6.0	9	No
							1.6	0.7		UDA					
18	24	M	Crush	LIF	2.0 × 2.5	2.0 × 3.5	1.8	1.0	90	UDA	1 DCV	DDN	6.5	8	No
19	32	M	Crush	LMF	1.5 × 2.0	1.5 × 2.5	1.6	0.8	100	RDA	2 DCV	TBRDN	5.0	11	No
20	24	M	Crush	LIF	1.5 × 2.5	1.5 × 3.0	1.8	1.0	95	UDA	1 DCV	TBRDN	7.0	6	No

M: Male; F: Female.
LIF: Left Index Finger; LMF: Left Middle Finger; LRF: Left Ring Finger; LLF: Left Little Finger; RIF: Right Index Finger; RMF: Right Middle Finger; RRF: Right Ring Finger; RLF: Right Little Finger; RDA: Radial Digital Artery; UDA: Ulnar Digital Artery; DCV: Dorsal cutaneous vein; VSV: Volar subcutaneous vein; TBRDN: Terminal branch of radial digital nerve; DDN: Dorsal digital nerve.

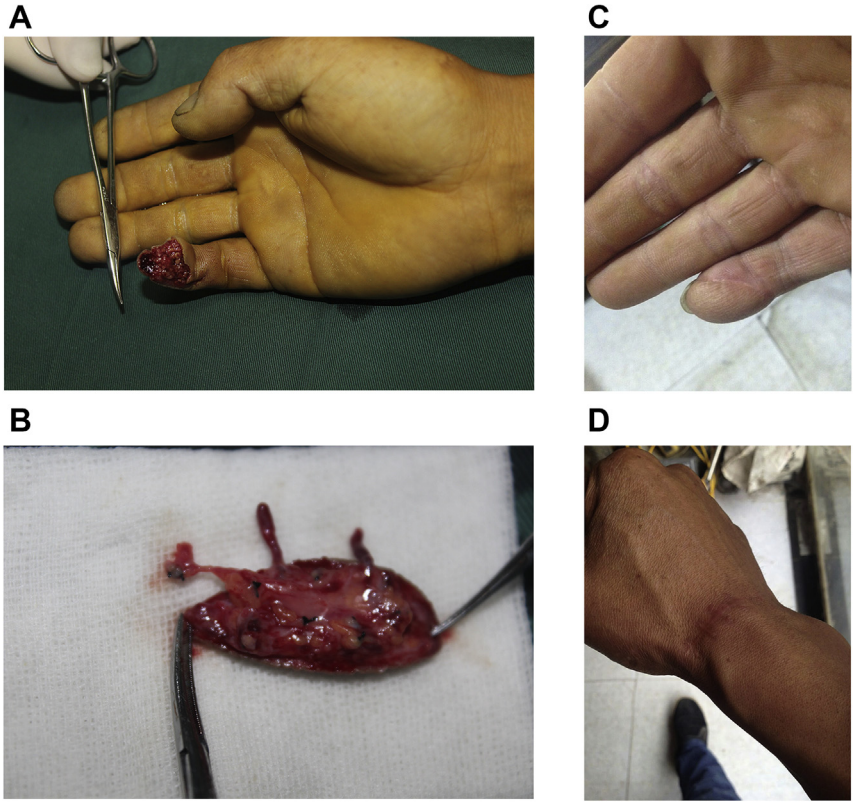

Figure 2 A 35-year-old male sustained a crush injury of his right little finger. (A) Crush injury of the right little fingertip. (B) Flap detached showing the much longer vein and nerve peripherally and the DRA/venae comitantes (C) Postoperative outcome at 28-month follow up of the flap (D) Postoperative outcome at 28-month follow up of the donor site.

texture of the flap matched the recipient site well and the donor site was closed directly (Figures 2C and D). The postoperative course was uneventful, and the long-term result was satisfactory (Figure 2C). Follow-up (28 months postoperatively) demonstrated that the flap was perfectly integrated from a functional and aesthetic point of view, and the static 2-point discrimination was 4.0 mm for the reconstructed fingertips (Figure 2C).

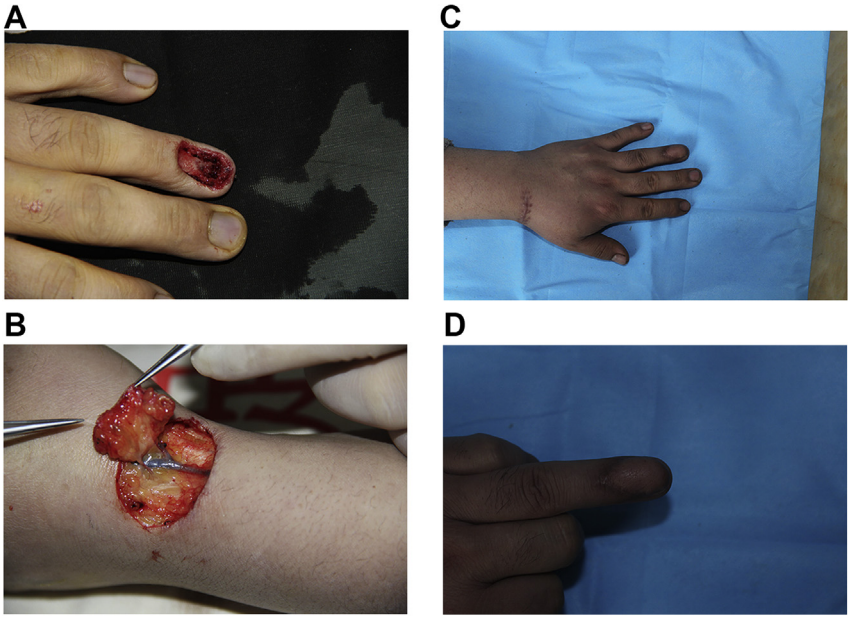

Figure 3 A 32-year-old man with an avulsion injury to the left ring finger. (A) A ring finger dorsum defect with exposure of the distal phalanx. (B) The DRA can be differentiated from a large radial artery as the vessel deviating into the anatomical snuffbox. (C) Postoperative dorsal view at 12 months after flap transfer (D) At 18-month follow-up, the dorsal view of the reconstructed finger.

Case 2

A 32-year-old male sustained a crush injury of his left middle finger, with soft tissue loss of the whole dorsal surface of the distal phalanx (Figure 3A). A free DRAP flap 2.0×2.5 cm^2 was harvested from the same hand. The flap was based on a DRAP branch of the radial artery (Figure 3B). The post-operative course was uneventful with satisfactory long-term outcomes (Figure 3C). 18-month follow-up the flap demonstrated good cosmetic results and static 2-point discrimination of 5.0 mm on the flap site (Figure 3D).

Case 3

A 32-year-old man sustained a fingertip crushing injury of his left middle finger with an electric saw (Figure 4A). According to his strong desire, a flap reconstruction was performed. This defect was reconstructed by using a 1.5×2.5 cm^2 free DRAP flap harvested from the same side of his forearm (Figure 4B). The free flap survived completely. The long-term result (11 months) was satisfactory, and the static 2-point discrimination was 5.0 mm for the resurfaced middle fingertip (Figure 4C).

Discussion

Fingertip injuries are common and reconstruction is heralding several challenges. Currently available flaps fail to offer satisfactory outcomes, aiming for an aesthetic soft tissue reconstruction with adequate sensation.[1] Current reconstructive options for fingertip soft tissue coverage include local digital artery perforator (DAP) flaps,[14] radial artery perforator (RAP) flaps,[15] and free flaps such as the second toe flap,[16] medial plantar artery perforator (MPAP) flaps[17] and dorsal metacarpal artery perforator (DMAP) flaps.[18] However, the locations and texture of these flaps will result in a bulky appearance and/or increase the donor site morbidity. Venous flaps have been described for larger re-surfacing hand and finger defects. However, post-operative swelling, bullae, and partial necrosis relatively occur especially when operative time is prolonged.[19] Moreover, procedures that require general anaesthetic due to large surgical dissection and prolonged overall time of surgery, make these reconstructive options less popular.[20] Our reconstructive option of a DRAP flap offers potential solutions, as it can be performed with a local or regional anaesthetic and has a relatively short operative time.

The dorsoradial artery (DRA) flap, first described by Bakhach et al. as a simple cutaneous antegrade flap was assuring vasculature utilizing a constant branch arising directly from the radial artery and is located at the apex of the first webspace.[11] The flap has been used as reverse local options for hand and fingers reconstruction,[21] however disadvantages relating to this options are attributed to the long scar, the transient numbness and the increasing donor site morbidity. Current literature lacks evidence in utilization and clinical outcomes of DRA based free flaps for hand reconstruction. Bakhach et al. first described the potential valuable use of this flap as a very small flap for fingertip reconstruction.[11]

Recent advancements in perforator flaps have replaced conventional major pedicle vessel based flaps, with the benefit of minimal donor site morbidity.[22] The major vessels are preserved without decreased perfusion to the skin territories of these flaps. The concept of perforator flap and supermicrosurgery[22,23] can be applied to the DRAP flap. Vascularization of the flap is ensured by a branch of the DRA at the level of the dorsum of the wrist. In our series, we found the pedicle of the DRA flap was constantly present and supplies the targeted area with a branch of the

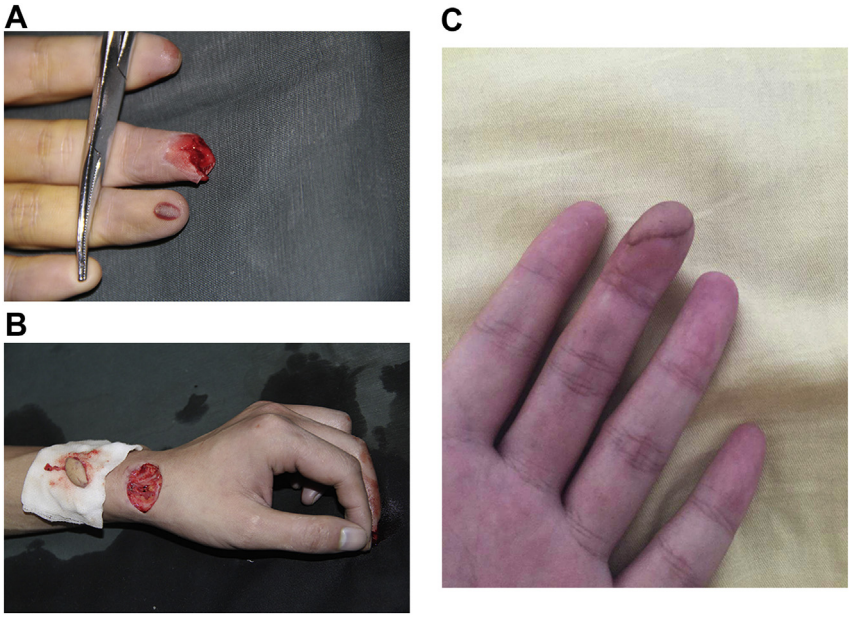

Figure 4 A 32-year-old man with a fingertip crushing injury of his left middle finger (A) Crush injury of the left middle fingertip. (B) The flap was elevated. (C) Postoperative result (volar) at 11-month follow up.

superficial branch of radial nerve constantly present in the dissection field, offering an innervated flap option, while preserving the main arterial supply to the hand.

Utilizing the DRAP flap offers advantages as it minimizes the operative time by allowing simultaneous preparation of the recipient and the donor site. It's feasible to be performed with regional anaesthesia using tourniquet in a single stage procedure. Moreover, aesthetic outcomes with skin texture and colour of same the characteristics, with the option of an innervated flap offering sensory reconstruction is available, however in hairy patients it may require hair removal.

The best option for partial amputation of the tip of a digit is as a microvascular replantation or as a composite graft.[24] Unfortunately, when the distal fingertip is not available or badly damaged free tissue transfer is required. Distal fingertip injuries with only skin loss potentially could be managed with minimal bone shortening or moist dressings and early mobilization, however those options compromise the digital length and the cosmetic outcomes.[25–27] In significant bone exposure, local options prove to be inadequate to fully reconstruct the wound defect. The type of flap reconstruction appropriate depends on the extent of tip loss and the configuration. Advancement flaps[28] may be able to manage wound coverage of transverse or oblique fingertip wounds, however, neurovascular advancement flaps are inadequate in size to reconstruct the palmar sloping tip defects. Neurovascular island flaps, such as the Littler flap, offer a good option but involve tedious dissection and a large palmar scar with the potential of secondary donor site morbidity.[29–31] Dorsal reverse metacarpal artery flaps require a skilled surgeon and confirmation of integrity of the vascular axis and are not an option for distal tip reconstruction, and controversial on previous history of trauma and crashing finger injuries.[32] The DRAP flap is a versatile and reliable flap offering a skin innervated paddle enough to reconstruct any digital defect of a similar size, provided a pulsatile artery and a venous drainage vessel is identified within the wound boarders. In our experience, DRAP is a neurovascular island flap which can be harvested with less palmar scarring and less challenging neurovascular pedicle dissection. However, the DRAP flap requires competency in supermicrosurgery microvascular technique for submillimeter small caliber vessels.

Conclusion

This case series demonstrates, for the first time, the versatility and reliability of the short pedicle free innervated DRAP flap as an option for the reconstruction of fingertip defects. In our experience, it has been proven to be a valuable option added to the armamentarium of the reconstructive surgeon specialized in supermicrosurgery techniques as it offers a thin, good textured, innervated flap with minimal donor site morbidity with optimal clinical outcomes.

Ethical approval

Not required.

Conflicts of interest

None declared.

References

1. Yan H, Fan C, Gao W, et al. Finger pulp reconstruction with free flaps from the upper extremity. *Microsurgery* 2012;**32**(5):406–14.
2. Rabarin F, Saint CY, Jeudy J, et al. Cross-finger flap for reconstruction of fingertip amputations: long-term results. *Orthop Traumatol Surg Res* 2016;**102**(4):S225–8.
3. Regmi S, Gu JX, Zhang NC, et al. A systematic review of outcomes and complications of primary fingertip reconstruction using reverse-flow homodigital island flaps. *Aesthet Plast Surg* 2016;**40**(2):277–83.
4. Lee YJ, Kim HY, Rha EY, et al. Esthetically successful fingertip reconstruction using a second toe pulp free flap with a split thickness skin graft and tattoo. *J Plast Reconstr Aesthet Surg* 2016;**69**(11):1574–6.
5. Sassu P, Lin CH, Lin YT, et al. Fourteen cases of free thenar flap: a rare indication in digital reconstruction. *Ann Plast Surg* 2008;**60**(3):260–6.
6. Song D, Deng X, Chen Y, et al. Thinned chimeric radial collateral artery perforator flap in complex distal thumb reconstruction. *Arch Orthop Trauma Surg* 2015;**135**(11):1623–31.
7. Li KW, Song DJ, Liu J, et al. Tripaddle posterior interosseous artery flap design for 3-finger defects: an evaluation of 3 surgical approaches. *Ann Plast Surg* 2016.
8. Park JU, Kim K, Kwon ST. Venous free flaps for the treatment of skin cancers of the digits. *Ann Plast Surg* 2015;**74**(5):536–42.
9. Inada Y, Tamai S, Kawanishi K, et al. Free dorsoulnar perforator flap transfers for the reconstruction of severely injured digits. *Plast Reconstr Surg* 2004;**114**(2):411–20.
10. Sen SK, Fitzgerald OE, Tare M. The free instep flap for palmar and digital resurfacing. *J Plast Reconstr Aesthet Surg* 2015;**68**(9):1191–8.
11. Bakhach J, Sentucq-Rigal J, Mouton P, et al. The dorsoradial flap: a new flap for hand reconstruction. Anatomical study and clinical applications. *Ann Chir Plast Esthet* 2006;**51**(1):53–60.
12. Mei J, Morris SF, Ji W, et al. An anatomic study of the dorsal forearm perforator flaps. *Surg Radiol Anat* 2013;**35**(8):695–700.
13. Zhang FH, Topp SG, Zhang WJ, et al. Anatomic study of distally based pedicle compound flaps with nutrient vessels of the cutaneous nerves and superficial veins of the forearm. *Microsurgery* 2006;**26**(5):373–85.
14. Mitsunaga N, Mihara M, Koshima I, et al. Digital artery perforator (DAP) flaps: modifications for fingertip and finger stump reconstruction. *J Plast Reconstr Aesthet Surg* 2010;**63**(8):1312–7.
15. White CP, Steve AK, Buchel EW, et al. Reverse radial artery flap perforator anatomy and clinical applications. *Ann Plast Surg* 2016;**77**(3):345–9.
16. Ju JH, Hou RX. One-stage cosmetic finger reconstruction using a second toe island flap containing terminal branches of the toe artery. *Orthop Traumatol Surg Res* 2015;**101**(3):345–51.
17. Huang SH, Wu SH, Lai CH, et al. Free medial plantar artery perforator flap for finger pulp reconstruction: report of a series of 10 cases. *Microsurgery* 2010;**30**(2):118–24.
18. Delikonstantinou IP, Gravvanis AI, Dimitriou V, et al. Foucher first dorsal metacarpal artery flap versus littler heterodigital neurovascular flap in resurfacing thumb pulp loss defects. *Ann Plast Surg* 2011;**67**(2):119–22.
19. Inoue G, Suzuki K. Arterialized venous flap for treating multiple skin defects of the hand. *Plast Reconstr Surg* 1993;**91**(2):299–302. discussion 303–6.

20. Woo SH, Kim SE, Lee TH, et al. Effects of blood flow and venous network on the survival of the arterialized venous flap. *Plast Reconstr Surg* 1998;**101**(5):1280—9.
21. Demiri EC, Dionyssiou DD, Pavlidis LC, et al. Soft tissue reconstruction of the thumb with the dorsoradial forearm flap. *J Hand Surg Eur Vol* 2013;**38**(4):412—7.
22. Koshima I, Yamamoto T, Narushima M, et al. Perforator flaps and supermicrosurgery. *Clin Plast Surg* 2010;**37**(4):683—9. vii-iii.
23. Koshima I, Nanba Y, Tsutsui T, et al. Medial plantar perforator flaps with supermicrosurgery. *Clin Plast Surg* 2003;**30**(3): 447—55. vii.
24. Elliot D, Moiemen NS. Composite graft replacement of digital tips. I. Before 1850 and after 1950. *J Hand Surg* 1997;**22B**: 341—5.
25. Allen MJ. Conservative management of finger tip injuries. *Hand* 1980;**12**:257—65.
26. Mennen U, Wiese A. Fingertip injuries management with semi-occlusive dressing. *J Hand Surg* 1993;**18B**:416—22.
27. Lee LP, Lau PY, Chan CW. A simple and efficient treatment for fingertip injuries. *J Hand Surg* 1995;**20B**:63—71.
28. Atasoy E, Ioakimidis E, Kasdan ML, Kutz JE, Kleinert HE. Reconstruction of the amputated finger tip with a triangular volar flap. *J Bone Jt Surg* 1970;**52A**:921—6.
29. Littler W. The neurovascular pedicle method of digital transposition for reconstruction of the hand. *Plast Reconstr Surg* 1953;**12**:303—31.
30. Sapp JW, Allen RJ, Dupin C. A reversed digital artery island flaps for the treatment of fingertip injuries. *J Hand Surg* 1993; **18A**:528—53.
31. Rose EH. Small flap coverage of hand and digit defects. *Clin Plast Surg* 1989;**16**:427—44.
32. Early MJ, Milner RH. Dorsalmetacarpaflaps. *Br J Plast Surg* 1987;**40**:333—41.