

D. Urriza Rodriguez
Southampton General Hospital, University Hospital
Southampton NHS Foundation Trust, Tremona Road,
Southampton, SO16 6YD, UK

S. Gujral
Department of Plastic Surgery, Royal Devon and Exeter
Hospital, Barrack Road, Exeter, Devon, EX2 5DW, UK

J. Smith
Department of Plastic Surgery, Bradford Royal Infirmary,
Duckworth Lane, BD9 6RJ, UK

DOI of original article: <http://dx.doi.org/10.1016/j.bjps.2016.02.011>

© 2016 British Association of Plastic, Reconstructive and Aesthetic Surgeons. Published by Elsevier Ltd. All rights reserved.

<http://dx.doi.org/10.1016/j.bjps.2016.05.025>

Microsurgical venous-branch-plasty for approximating diameter and vessels' Position in lymphatic supermicrosurgery



Dear Sir,

Lymphatic supermicrosurgery, supermicrosurgical lymphaticovenular anastomosis (LVA), is becoming popular surgical treatment for compression-refractory lymphedema due to its effectiveness and minimal invasiveness.^{1,2} It is important to find a lymphatic vessel with abundant lymph flow and a vein with an intact valve to prevent post-anastomotic venous reflux and subsequent anastomosis site thrombosis.^{2,3} Finding lymphatic vessels suitable for LVA is significantly facilitated with the use of indocyanine green lymphography, but it is difficult to prevent venous reflux after anastomosis especially when there is only a large vein distant from a lymphatic vessel.^{4,5} Vein grafting can prevent venous reflux, but requires additional scar to harvest a vein. To address this challenge, we adopted a new technique, microsurgical venous-branch-plasty (MVP), in lymphatic supermicrosurgery.

There was a large (2.0 mm) vein distant from a 0.5-mm lymphatic vessel. Since there was a significant distance between the vessels and a significant diameter discrepancy, it was impossible or inappropriate to anastomose them directly in a conventional manner such as end-to-end, end-to-side, side-to-end, or side-to-side fashion. To approximate the vessels and to minimize the vessels' size discrepancy, the vein was incised and split; 1 × 10 mm venous wall flap was raised, and the both edges of the donor vein and the flap were sutured using running 10-0 nylon microsutures to create a neo-branch while preserving the native venous flow

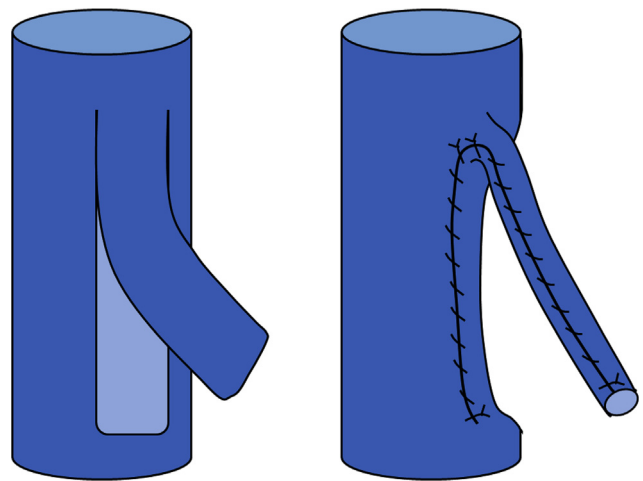


Figure 1 A schematic drawing of microsurgical venous-branch-plasty. A 2.0-mm vein was incised to raise a 1 × 10 mm venous wall flap (left). The both edges of the donor vein and the flap were sutured to create a neo-branch (right).

(Figure 1). The base of the flap was sutured to make the neo-branch lumen narrow; the narrow branching point could act as a valve. The created neo-venous branch could be easily approximated and anastomosed to the lymphatic vessel in a

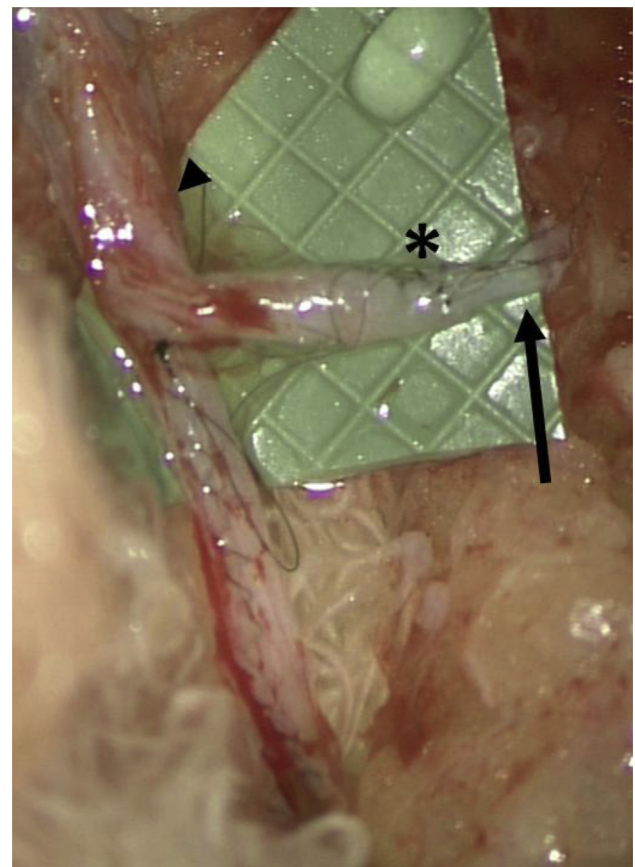


Figure 2 Microsurgical venous-branch-plasty for supermicrosurgical lymphaticovenular anastomosis (asterisk) using a large vein (arrowhead) distant from a lymphatic vessel (arrow).

conventional end-to-end LVA fashion, and there was no venous reflux seen after anastomosis thanks to the valve-like structure (Figure 2).¹

This is the first report of MVP in lymphatic supermicrosurgery to our knowledge. MVP can be helpful when there is only a large vein distant from a lymphatic vessel. Although indication is limited and further study is required to confirm its efficacy, MVP has a potential to be a useful method to allow direct anastomosis to a lymphatic vessel using a distant large vein without additional sacrifice.

Ethics

Reported under Tokyo Metropolitan Bokutoh Hospital ethics committee-approved protocol.

Conflicts of interest

None.

Disclaimers and disclosure

None.

Funding

None.

Prior presentations

None.

Acknowledgments

The first author (T.Y.) would like to thank Nana and Rico for their kind support to manuscript preparation.

References

1. Yamamoto T, Narushima M, Kikuchi K, et al. Lambda-shaped anastomosis with intravascular stenting method for safe and effective lymphaticovenular anastomosis. *Plast Reconstr Surg* 2011;127(5):1987–92.
2. Yamamoto T, Narushima M, Yoshimatsu H, et al. Minimally invasive lymphatic supermicrosurgery (MILS): indocyanine green lymphography-guided simultaneous multi-site lymphaticovenular anastomoses via millimeter skin incisions. *Ann Plast Surg* 2014;72(1):67–70.
3. Yamamoto T, Koshima I. In situ vein grafting for lymphatic supermicrosurgery. *J Plast Reconstr Aesthet Surg* 2014 May;67(5):e142–3.
4. Yamamoto T, Yoshimatsu H, Koshima I. Navigation lymphatic supermicrosurgery for iatrogenic lymphorrhea: supermicrosurgical lymphaticolymphatic anastomosis and lymphaticovenular anastomosis under indocyanine green lymphography navigation. *J Plast Reconstr Aesthet Surg* 2014 Nov;67(11):1573–9.
5. Yamamoto T, Narushima M, Doi K, et al. Characteristic indocyanine green lymphography findings in lower extremity

lymphedema: the generation of a novel lymphedema severity staging system using dermal backflow patterns. *Plast Reconstr Surg* 2011;127(5):1979–86.

Takumi Yamamoto

Department of Plastic Surgery, Tokyo Metropolitan
Bokutoh Hospital, Tokyo, Japan

E-mail address: tyamamoto-ky@umin.ac.jp

Guido Giacalone

Department of Lymphatic Surgery, AZ Sint-Maarten
Hospital, Duffel, Belgium

Akitatsu Hayashi

Department of Plastic Surgery, Asahi General Hospital,
Chiba, Japan

© 2016 British Association of Plastic, Reconstructive and Aesthetic Surgeons. Published by Elsevier Ltd. All rights reserved.

<http://dx.doi.org/10.1016/j.bjps.2016.02.004>

Refinements in dynamic external fixation for optimal fracture distraction in pilon-type fractures of the proximal interphalangeal joint



Dear Sir,

Many different techniques have been described for the management of pilon-type fractures of the proximal interphalangeal joint.^{1,2} Suzuki and colleagues described the use of pins and rubber traction,³ with Agarwal and Pickford describing technical refinements to their technique.¹ In 2001 Hynes and Giddins described a simple technique involving dynamic external fixation, which did not require special equipment and was simple to learn and perform.⁴ Their frame avoided many problems of the Suzuki frame, such as appropriate adjustment of rubber band tension in subsequent hand clinic and therapy sessions.

We describe some technical refinements that will optimize application of the Hynes and Giddins frame. We use a series of illustrations to demonstrate the steps of frame application (Figures 1 and 2). The procedure can be performed under local or regional anaesthesia. Hypodermic needles are used as radiological markers to guide optimal placement of the two transverse Kirschner (K) wires⁵; that is a) through the head of the proximal phalanx and b) approximately halfway along the shaft of the middle phalanx (Figures 1 and 2). These positions can then be marked in ink. The K wires should be 1.1 mm (smaller wires have insufficient strength) and the proximal transverse wire inserted first. The exact placement of the distal transverse wire is determined later in our technique, in comparison to